

# Segmentation Algorithm for CT Images Using Morphological Operation and Artificial Neural Network

C. Karthikeyan and B. Ramadoss

**Abstract**—Segmentation of pulmonary X-ray computed tomography (CT) images is a precursor to most pulmonary image analysis applications. Digital Image Processing is currently a hot research area in medicine and it is believed that they will receive extensive application to biomedical systems in the next few years. In Digital Image Processing, neural networks are ideal in recognizing diseases using scans since there is no need to provide a specific algorithm on how to identify the disease. This paper describes an algorithm to separate the lung tissue from a Chest CT to reduce the amount of data that needs to be analyzed. Our goal is to have a fully automatic algorithm for segmenting the lung tissue, and to separate the two lung sides as well. Fuzzy c-Means clustering is used to segment the lungs. Cleaning is performed to remove air, noise and airways. Finally, a sequence of morphological operations is used to smooth the irregular boundary. The database used for evaluation is taken from a radiology-teaching file. Our current evaluation shows that the applied segmentation algorithm works on a large number of different cases. The textural features were extracted from the segmented lungs and it was given as input to CFBP. The neural networks are used to identify the various lung diseases.

**Index Terms**—CFBP, Lung Extraction, Lung Diseases, Fuzzy C-means clustering

## I. INTRODUCTION

High-resolution X-ray computed tomography (CT) is the standard for pulmonary imaging. Depending on the scanner hardware, CT can provide high spatial and high temporal resolution, excellent contrast resolution for the pulmonary structures and surrounding anatomy, and the ability to gather a complete three-dimensional (3-D) volume of the human thorax in a single breath hold [1]. Pulmonary CT images have been used for applications such as lung parenchyma density analysis [16], airway analysis [3], and lung and diaphragm mechanics analysis [4]. A precursor to all of these quantitative analysis applications is lung segmentation. With the introduction of multislice spiral CT scanners, the number of volumetric studies of the lung is increasing and it is critical to develop fast, accurate algorithms that require minimal to no human interaction to identify the precise boundaries of the lung. A number of groups have developed techniques for computer assisted segmentation of pulmonary CT images

[16], [5]. In [6], manually traced boundaries were used to estimate regional gas and tissue volumes in the lungs of normal subjects. But manual methods are laborious. In an X-ray CT the natural contrast between the low-density lungs and the surrounding high-density chest wall can be used to guide image segmentation. In [16] 2-D edge tracking was used to find the boundaries of the left and right lungs. Others have used 3-D region growing with manually specified seed points [7]. In many semi-automatic approaches, some manual interaction is required to select threshold values or edit the resulting segmentation [16]. More recently, Brown *et al.* [8] provided a knowledge-based, automatic method to segment chest CT images. In their method, anatomic knowledge stored in a semantic network is used to guide low-level image processing routines. Segmentation algorithms for lung CTs in the literature are mostly pixel-based methods [9], [10]. In pixel-based methods, the first idea is to eliminate fat tissue and bones. As the lung parenchyma has a very low-density, it is composed of low-intensity pixels in the CT scan. This property is exploited to separate the two lungs from the surrounding tissue. Many studies have revealed that CAD systems are effective at detecting small pulmonary nodules on CT [12-15], and the ultimate goal of CAD systems is the detection of lung diseases. Armato *et al.* [2] reported that a large fraction of missed lung cancers were detected using a CAD system. This paper is organized as follows. Section II gives a detailed description of the method. Section III provides experimental results and section IV contains a discussion and summary.

## II. METHOD

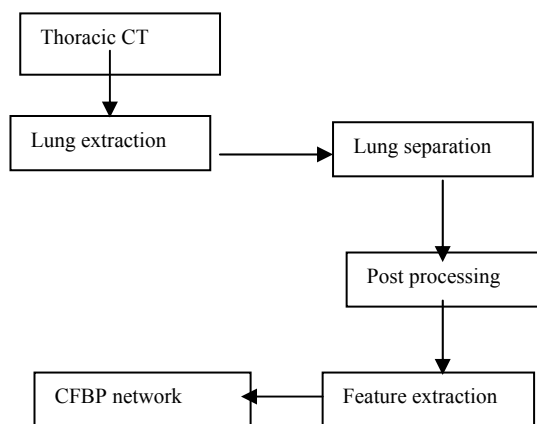


Fig. 2.1. System structure.

We assume that the input data is 2-D thoracic CT, which is in JPEG format. The data set should include thorax from the trachea to below the diaphragm. In the CT image data, air

Manuscript received May 4, 2011; revised July 25, 2011.

C. Karthikeyan, Associate Prof. and Head / IT / AVIT, PhD (CSE), Research Scholar, Jawaharlal Nehru Technological University, Hyderabad, India (email: ckarthik2k@gmail.com)

B. Ramadoss, Professor and Head, Department of Computer Applications, National Institute of Technology, Tiruchirappalli, India

will appear with a mean intensity of approximately -1000 Hounsfield units (HU), most lung tissue will be in the range of -910 HU to -500 HU, while the chest wall, blood and bone will be much more dense (above -500 HU). As shown in Fig. 2.1, this method consists of five main steps: an extraction step to identify the lungs, a separation step to separate the right and left lungs, smoothing step to smooth the lung boundaries, feature extraction step to extract texture features and last step is to classify the lung diseases using Back Propagation neural network and Feed forward cascade neural network.

#### A. Lung Extraction

##### 1) Fuzzy C-means Clustering

Fuzzy c-means (FCM) is a method of clustering which allows one piece of data to belong to two or more clusters. Fuzzy partitioning is carried out through an iterative optimization of the objective function. This procedure converges to a local minimum. Fuzzy c-Means clustering is used to segment the lungs. The maximum Number of iterations specified is 100. The termination criterion is fixed as .00001. The pixels of the input image are divided into 2 clusters. The first cluster includes pixels in the lungs (body pixel). The second cluster includes pixels in the thoracic CT other than lungs (non-body pixel). The pixels corresponding to the first cluster is determined.

##### 2) Background Removal

Rarely holes can appear near the border of the parenchyma. To fill these holes and glue different parts of a same lung together, a rolling ball operator is applied. Rolling ball operator is in fact a morphological closing of the region followed by hole filling. A hole is a set of background pixels that cannot be reached by filling in the background from the edge of the image. As the air around the body has a very similar intensity to the lungs it will not be discarded by the thresholding, so it has to be removed. Further steps are performed to improve the result. Back ground pixels are identified as follows: They are non-body pixels and pixels connected to the border. Thus every connected region of non-body pixel that touches the border is considered as background and discarded.

#### B. Lung Separation

The segmented lungs must be identified and separated. The region is simply cut vertically in the middle. And the resultant image is multiplied with the original image to get the right and left lungs.

#### C. Post-Processing

The morphological operations such as opening followed by closing are again applied after separating the lungs to smooth it. The morphological operations is defined by

$$f * b = (f \circ b) \bullet b$$

where  $f$  is the target image,  $b$  is the structuring element,

$\bullet$  means morphological closing,

$\circ$  means morphological opening the images obtained after applying disc based structuring element are multiplied with the original image to get the segmented lungs.

#### D. Feature Extraction

##### 1) Covariance Features

Auto-correlation coefficients reflect the inter-pixel correlation within an image. It is a Mean removed version also called Modified Auto Covariance features. Let the given image has size  $M \times N$ . The modified auto-covariance coefficients is given by

Where

$$\gamma(\Delta m, \Delta n) = 1 - A(\Delta m, \Delta n) / A(0,0)$$

$$A(\Delta m, \Delta n) = 1 / (M - \Delta m)(N - \Delta n)^*$$

$$M-1-\Delta m \quad N-1-\Delta n$$

$$\sum_{x=0} \sum_{y=0} (f(x,y) - mn)(f(x+\Delta m, y+\Delta n) - mn)$$

$$\Delta m = 0 \dots a$$

$$\Delta n = 0 \dots b$$

$$a = 1 \dots 4$$

$$b = 1 \dots 4$$

#### E. Classification Of Lung Diseases

##### 1) Cascade Forward back propagation

The commonest type of artificial neural network consists of three groups, or layers, of units: a layer of "input" units is connected to a layer of "hidden" units, which is connected to a layer of "output" units. The activity of the input units represents the raw information that is fed into the network. The activity of each hidden unit is determined by the activities of the input units and the weights on the connections between the input and the hidden units. The behavior of the output units depends on the activity of the hidden units and the weights between the hidden and output units. The behavior of an ANN (Artificial Neural Network) depends on both the weights and the input-output function (transfer function) that is specified for the units.

Cascade-forward is a feed forward network with the exception that it starts with a minimal number of hidden layer neurons. During back propagation additional neurons are added to hidden layer as needed to improve classification. CFBP is just like BPN. It is also using back propagation algorithm for updating weights. But main symptom of this network is that each layer neurons closely related to all previous layer neurons. Training process towards these networks is iterative. When the error between desired value and predicted value became minimum, training process towards stability.

### III. EXPERIMENTAL RESULTS

The thoracic CT images [Fig. 3.1] were downloaded from the website [10] and it is in JPEG format. The iterative procedure is invoked till convergence is reached. The input to FCM is the intensity of all pixels in an image. The number of clusters is two. One cluster corresponds to body pixels and other non-body pixels. From the center point of the clusters the identification of cluster belongs to body pixels is done. The background pixels from a thresholded image [Fig. 3.2] are removed.

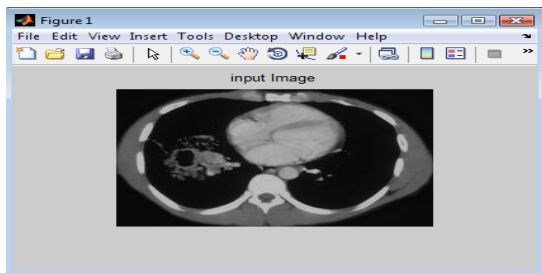


Fig. 3.1. Input Image-Thoracic CT.

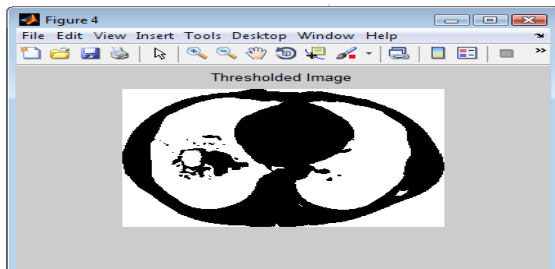


Fig. 3.2. Thresholded Image

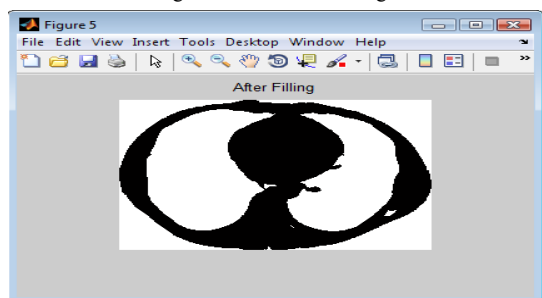


Fig. 3.3. After Applying Rolling Ball Operator

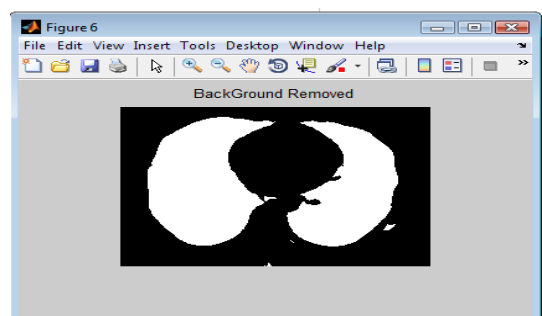


Fig. 3.4. After Removing Background

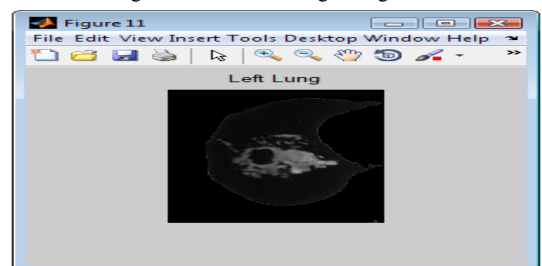


Fig. 3.5. (a) Separated Lungs – Left Lung

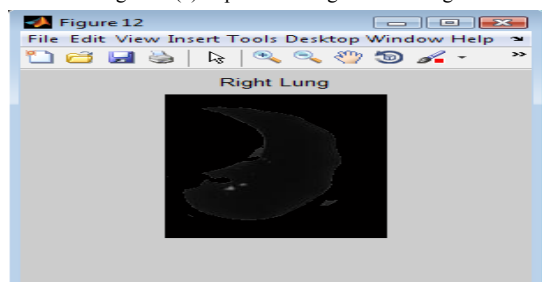


Fig. 3.5. (b) Separated Lungs – Right Lung

Rolling ball operator is applied to remove small holes

inside the lung cavity. [Fig. 3.3]. The background pixels are eliminated [Fig. 3.4]. Finally the lungs are separated and morphological opening followed by closing is applied [Fig. 3.5]. The ball based structuring element with radius 4 and height 1 is used for opening and the same structuring element with radius 2 and height 1 is used for closing.

The separated lungs are given as input to feature extraction module. Covariance features for both right and left lungs are found and is averaged for each thoracic CT. The average feature is given as input to cascade forward back propagation neural network to classify the lung diseases. The performance of the system is analyzed for various inter-pixel distances. The number of neurons in the input layer depends upon the number of features. The number of neurons in the hidden layer is two. The number of epochs used for training is 100. The number of training patterns is 15. The number of testing patterns is 20. The inter-pixel distance 3 gives more accuracy.

#### IV. SUMMARY

This paper shows a simple segmentation algorithm for thoracic CT images. Several techniques are used for segmentation such as, Fuzzy c-Means clustering mathematical Morphology and connected component analysis. An evaluation of the segmentation quality shows good output by visual results. The segmentation algorithm proves to be simple but effective. The texture features are extracted from both right and left segmented lungs and it is given as input to CFBP. Thus CFBP is used to classify lung diseases.

#### REFERENCES

- [1] E. A. Hoffman and G. McLennan, "Assessment of the pulmonary structure-function relationship and clinical outcomes measures: Quantitative volumetric CT of the lung," *Academic Radiol.*, vol. 4, no. 11, pp. 758-776, 1997.
- [2] Armato SG 3rd, Li F, Giger ML, MacMahon H, Sone S, Doi K." Lung cancer: performance of automated lung nodule detection applied to cancers missed in a CT screening program" *Radiology* 2002; 225:685-692
- [3] I. Amirav, S. S. Kramer, M. M. Grunstein, and E. A. Hoffman, "Assessment of methacholine- induced airway constriction by ultrafast high-resolution computed tomography," *J. Appl. Physiol.*, vol. 75, no. 5, pp.2239-2250, 1993.
- [4] E. A. Hoffman, T. Behrenbeck, P. A. Chevalier, and E. H. Wood, "Estimation of regional pleural surface expansile forces in intact dogs," *J. Appl. Physiol.*, vol. 55, no. 3, pp. 935-948, 1983.
- [5] W. A. Kalender, H. Fichte, W. Bautz, and M. Skalej, "Semiautomatic evaluation procedures for quantitative CT of the lung," *J. Comput. Assist. Tomogr.*, vol. 15, no. 2, pp. 248-255, 1991.
- [6] D. M. Denison, M. D. L. Morgan, and A. B. Millar, "Estimation of regional gas and tissue volumes of the lung in supine man using computed tomography," *Thorax*, vol. 41, pp. 620-628, 1986.
- [7] E. A. Hoffman and E. L. Ritman, "Effect of body orientation on regional lung expansion in dog and sloth," *J. Appl. Physiol.*, vol. 59, no. 2, pp. 481-491, 1985
- [8] M. S. Brown, M. F. McNitt-Gray, N. J. Mankovich, J. G. Goldin, J.Hiller, L. S. Wilson, and D. R. Aberle, "Method for segmenting chest CT image data using an anatomical model: Preliminary results," *IEEE Trans. Med. Imag.*, vol. 16, pp. 828-839, Dec. 1997.
- [9] S. Hu, E. A. Hoffman, and J. M. M. Reinhardt, "Automatic lung segmentation for accurate quantitation of volumetric X-ray CT images," *IEEE Transactions on Medical Imaging*, vol. 20, no. 6, pp. 490-498, 2001.
- [10] J. K. Leader, B. Zheng, R. M. Rogers, F. C. Sciruba, A. Perez, B. E. Chapman, S. Patel, C. R. Fuhrman, and D. Gur, "Automated lung

segmentation in X-ray computed tomography: Development and evaluation of a heuristic threshold-based scheme,” Academic Radiology, vol. 10, pp. 1224–1236, 2003.

- [11] Ock-Kyung Yoon; Dong-Min Kwak; Dong-Whee Kim; Kil-Houm Park, “MR Brain Segmentation using fuzzy clustering”, IEEE International Conference on Fuzzy Systems Proceedings, 1999. FUZZ-IEEE '99.
- [12] Goo JM, Lee JW, Lee HJ, Kim S, Kim JH, Im JG, “Automated lung nodule detection at low-dose CT: preliminary experience”, Korean J Radiol 2003;4:211-216
- [13] Lee IJ, Gamsu G, Czum J, Wu N, Johnson R, Chakrapani S, “Lung nodule detection on chest CT: evaluation of a computer aided detection (CAD) system”, Korean J Radiol 2005;6:89-93
- [14] Lee JW, Goo JM, Lee HJ, Kim JH, Kim S, Kim YT, “The potential contribution of a computer-aided detection system for lung nodule detection in multidetector row computed tomography”, Invest Radiol 2004;39:649-655
- [15] D. Vijendrababu and N.R.Alamelu, “EBCOT using Energy Efficient Wavelet Transform”, International Conference on Computing, Communication & Networking, 2008. IEEE Explore - Digital Object Identifier: 10.1109/ ICCCNET.2008.4787746
- [16] L. W. Hedlund, R. F. Anderson, P. L. Goulding, J. W. Beck, E. L. Effmann, and C. E. Putman, “Two methods for isolating the lung area of a CT scan for density information,” Radiology, vol. 144, pp. 353–357, 1982.



**Karthikeyan** is Associate Professor and Heading the Department of Information Technology, Aarupadai Veedu Institute of Technology, Tamilnadu. He is holding Master’s Degree in Computer Science and Engineering and pursuing PhD from JNTU, Hyderabad. Published many papers in various National and International Conferences and Journals. He is also the reviewer and member of the editorial board of the journal “International Journal of Computer Science and Technology” (IJCST). He is life member in Indian Society for Technical Education(ISTE), International Association of Computer Science and Information Technology(IACSIT) and Association of Computer Electronics and Electrical Engineer(ACEEE).



**B. Ramadoss** is serving as a Professor and Head in the Department of Computer Applications, National Institute of Technology, Trichy. Received ME in Computer Science & Engineering from IIT, Delhi. and PhD from IIT, Bombay. He is the Life Member of ISTE and CSI. He is the trained Assessor in Computer Applications for NBA. Received prize by the Central Board of Irrigation and Power, New Delhi, for the paper published in the Irrigation and Power Journal and Best Teacher Award in Computer Applications for the year 2006-2007 from National Institute of Technology, Tiruchirapalli. He is Reviewer of the International Journal of Intelligent Systems Technologies and Applications.